

# 脐针介绍 An Introduction to Navel Acupuncture Therapy



冯立博士 Dr. Jessica Li Feng

新西兰中医学院

New Zealand College of Chinese Medicine

12/11/20

16

## Topics 主要内容

1. Introduction to navel acupuncture 易医脐针  
基本介绍
2. The characteristics of Yi medicine navel  
acupuncture 易医脐针的针法特点
3. General principles of navel needling  
position 脐针的定位进针原则
4. Clinical application - Case discussion 临床应  
用 - 病例分析
5. Conclusion 结论


12/11/20  
16

## 1. Introduction to navel acupuncture 易医脐针基本介绍

- ▶ Navel Acupuncture was invented by Professor Yong Qi and it was called "Qi's Umbilical Diagnosis and Qi's Navel Acupuncture Therapy". 脐针是有齐永教授发明的，故可称为“齐氏脐诊”和“齐氏脐针疗法”。
- ▶ Navel Acupuncture Therapy was discovered by chance in 1995; as a new therapy it was invented and completed over ten years of practice and research work. 齐永教授于1995年一次偶然的机会发现了脐针，通过十多年的临床实践与研究形成完整体医学体系

12/11/20  
16

### 1.1 Navel acupuncture founder Professor Yong Qi 脐针创始人齐永教授



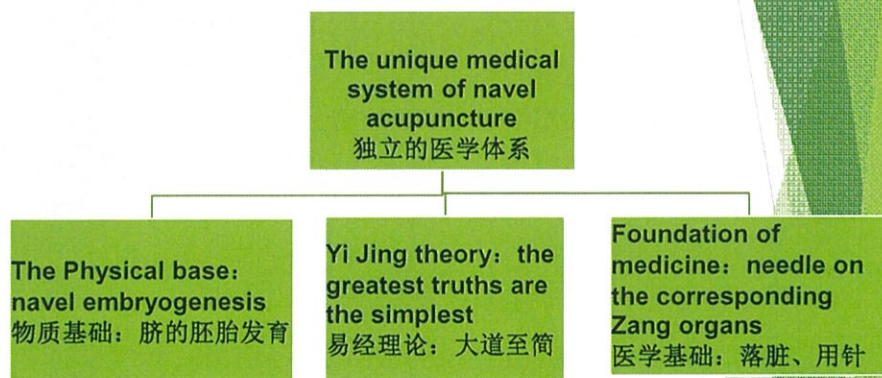
12/11/20  
16



## 1.2 Professor Qi's Publications



## 1.3 The composition of Yi medicine navel acupuncture 易医脐针的组成



12/11/20  
16

## 1.4 The three essential factors

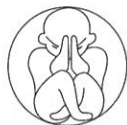### 脐针三要素

**Practical and rapid  
clinical effect**  
实用快速的临床疗效

**Easy and quick start**  
简便快捷的入手方式

**Profound sources of Yi  
medical culture**  
根源深厚的易医文化

12/11/20  
16



## 1.5 The significance of navel acupuncture 脐针的意义

1. Ending the contraindication of "forbidden needling on the navel" 终结了“神阙禁针”的禁锢
2. Renewing the medical treatment concept which relates to *Yi Jing* theory 恢复了易经指导医学的治医理念
3. Developing the first single point for treatment in medical history 开启了单穴治病的先河
4. Embodying the advantages of Chinese medicine treatment 体显了中医的疗疾优势

12/11/20  
16



## 1.6 The differences between navel acupuncture and other needling 易医脐针与其它针法的不同

Differences	Navel Acupuncture	Traditional Acupuncture
Theory 理论	Yi medicine 易医	Chinese medicine 中医
Treatment 治疗	Location therapy 定位治疗	Fixed point treatment 定点治疗
Holograms 全息	holographic information 信息全息	Structural hologram 结构全息
Meridian Qi 经气	Congenital meridian qi 先天经气	Acquired meridian qi 后天经气

12/11/20  
16

## 2. The characteristics of Yi medicine navel acupuncture 易医脐针的针法特点

1. One point with multiple needles 一穴多针
2. One point with multiple treatments 一穴多治
3. One point with multiple functions 一穴多效
4. Location of therapy 定位治疗
5. Direction reinforcing and reducing 方位补泻
6. Addresses both the symptoms and root causes 内外兼治
7. Easy operation 操作简便

12/11/20  
16

### 3. General principles of navel needling position 脐针的定位进针原则

- 3.1 Needle on the tender point of umbilical wall 针法进压痛点位
- 3.2 Pressing on subcutaneous nodules of the umbilical wall 寻找皮下定结节法
- 3.3 Needle method according to the umbilical hologram of Luoshu 脐洛书进针法
- 3.4 Needle on the umbilical Bagua regions 脐八卦定位进针法
- 3.5 Needle on the umbilical regions which are divided into the twelve earthly branches 脐十二地支进针法

12/11/20  
16

#### 3.1 Needle on the tender point of the umbilical wall 针法进压痛点位

- Often about 20% of patients have very sensitive points and tenderness on the umbilical wall; also it has been noticed that these tender points are more obvious when the patient's condition is more acute.  
约有百分之二十左右病人可以在脐壁找到十分敏感的压痛点，越是急性病，压痛部位越明显。

12/11/20  
16



### 3.2 Pressing on subcutaneous nodules of the umbilical wall 寻找皮下定结节法

- Many patients with chronic diseases can be found to have subcutaneous nodules on the umbilical wall. 有许多慢可以在脐壁上找到皮下结节。
- Pressing the nodules several times a day, can cause the nodules to disappear after a few weeks, and the disease is cured. 用手指按压, 让病人感到疼痛即可, 每日数次, 数周后结节消失, 疾病也就治愈

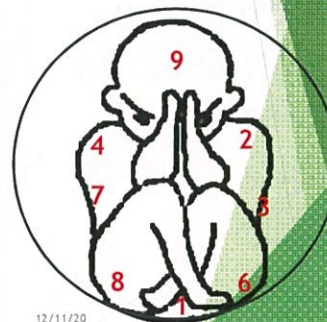
12/11/20  
15

### 3.3 Needle method according to the navel hologram of Luoshu 脐洛书进针法

The original text from Luo Shu 《洛书》 says, "Number nine is head and one is feet, Left three and right seven are waist, two and four are shoulders, six and eight are thighs, five is in the center".

洛书云：“戴九履一，左三右七为腰，二四为肩，六八为足，五居于中。”

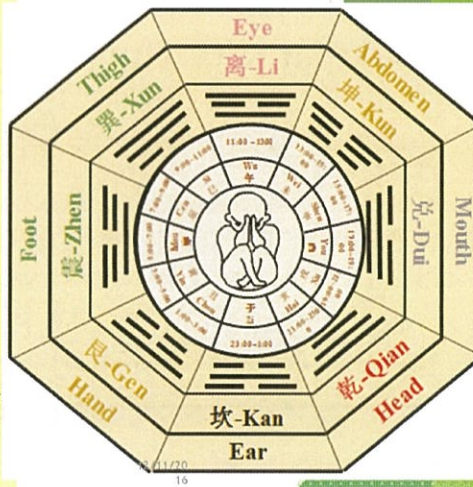
4	9	2
3	5	7
8	1	6

12/11/20  
16

### 3.4a Needle on the outer Bagua regions 脐外八卦进针法

Qian 乾 region represents the head, Kun 坤 region represents the abdomen, Zhen 震 region represents the foot, Xun 巽 region represents the thigh, Kan 坎 region represents the ear, Li 离 region represents the eye, Gen 艮 region represents the hand, Dui 兑 region represents the mouth

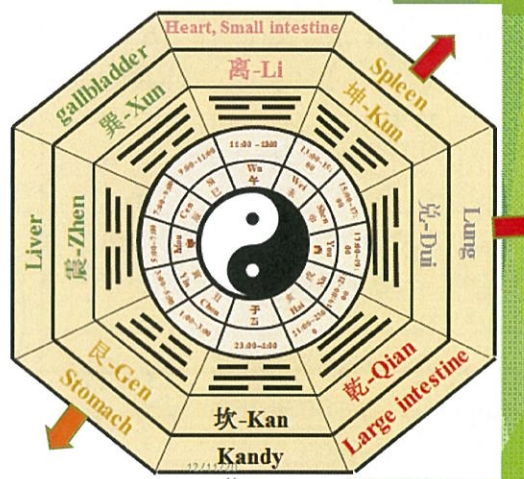
乾为首，坤为腹，震为足，巽为股，坎为耳，离为目，艮为手，兑为口



### 3.4b Needle on the inner umbilical Bagua regions 脐内八卦进针法

E.g., Kun Gua represents the earth region controlling the spleen.

例如，坤卦为脾脏。

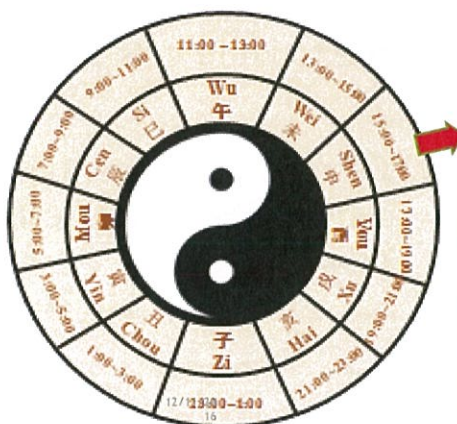



### 3.5 Needle on the umbilical regions which are divided by the twelve earthly branches 脐十二地支进针法

E.g. in the Shen申 region which is the Bladder meridian area, we can treat Bladder meridian problems.

例如，申时是膀胱经的时间，可治疗膀胱经的问题。



### 3.6 The contraindication of Navel Acupuncture 脐针禁忌症项

Perpendicular needling is forbidden !

严禁直刺 !

## 4. Clinical application - Case discussion 临床应用 - 病例分析

4.1 Case 1 : left middle finger infection due to knife cut 病例1 左中指刀割伤后感染

4.2 Case 2 : left lower limb joint comminuted fractures 病例2 左下肢多处粉碎性骨折

12/11/20  
16

### 4.1 Case 1 : Left middle finger infection due to knife cut 病例1 : 左中指刀割伤后感染

- Female 49 years old European Caucasian. Left middle finger infection for 8 days due to knife cut. She felt severe pain. PE: left middle finger can't flex, swollen, skin colour was dark purple; both pulses were thready and weak. There was a long thin nodule inferior and lateral to the left guan and chi area.

洋人女性，49岁。左中指刀割伤后感染8天，局部疼痛剧烈，难以忍受，PE：左中指不能伸曲，局部肿胀，皮肤一片紫黑色，双脉细弱无力，左关尺下外有一细长硬条状物。

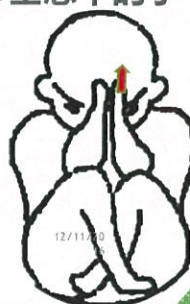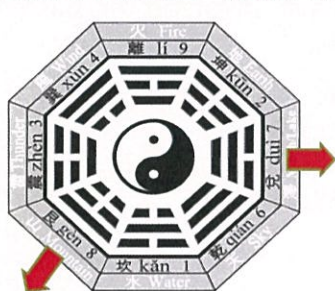12/11/20  
16



#### 4.1a Case1 : Treatment process of left middle finger infection based on navel needling

##### 病例1：脐针治疗左中指感染

- She was treated with the navel needle method with dredging the qi and blood circulation by combination of mountain (shan) and marsh (ze), and the point corresponding to the middle finger based on the Luo shu holographic theory. 易医脐针疗法：山泽通气和洛书人体全息中的手一针。



#### 4.1b Case1 : The treatment effect of the left middle finger infection based on navel needling

##### 例1：脐针治疗后疗效

治疗前 Before the treatment	留针 30 分钟时 Retain needles for 30 min	55 分后起针时 55 min when withdraw needles
		

12/11/2016

16

## 4.2 Case 2 left lower limb joint comminuted fractures 病例 2 左下肢多处粉碎性骨折

- ▶ Female, 53 years old. Tripped down stairs and had a hyper plantarflexion injury to her left foot. Pain, swelling and cold, unable to weight bear for 5 days.
- ▶ CT scan on her foot 21/9/2016: Left metatarsophalangeal Joint comminuted fractures involving the distal medial cuneiform and base of the second metatarsal. Fractures also involved the base of the 1<sup>st</sup>, 3<sup>rd</sup> and 4<sup>th</sup> metatarsals.

53岁，女性，左下肢疼痛难以忍受、局部水肿冰冷、不能承重5天，因踩空楼梯台阶摔倒，致左脚背跖曲骨受伤所致。2016年9月21号 脚部CT显示：跖跗关节粉碎性骨折，牵连远端内侧楔状骨和第二跖骨底粉碎性骨折，第一、三和四跖骨底骨折。

12/11/20  
16

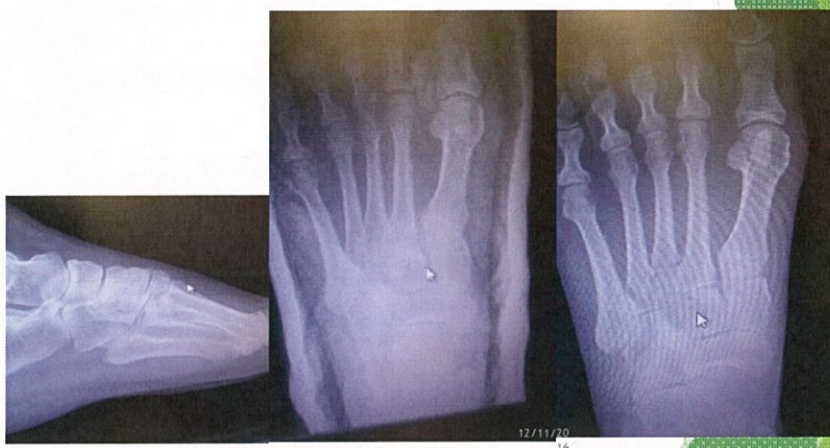### 4.2a Case2 : Treatment for comminuted fractures of left lower limb based on navel needling 病例2 脐针治疗左下肢多处粉碎性骨折

- ▶ After navel needling Lei and Shui, the left foot was changing from cold to warm, just as in a hot foot bath. The warm feeling stayed for 11 hours and the patient felt very comfortable after needling. The patient was treated another 9 times, each time she had the similar warm feeling. 用雷水解后，原来冰冷的左脚变温热如同热水足浴，维持了整整11小时，病人说针后很舒服，后又治疗了8次，每次都有类似热水足浴的感觉。

12/11/20  
16

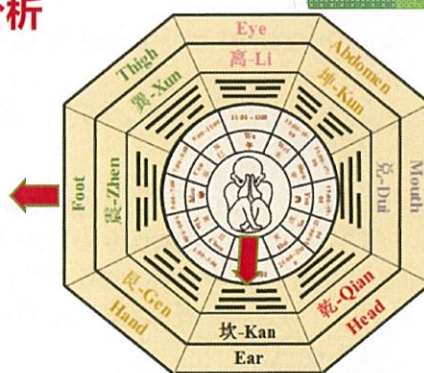


## Foot X-ray on 21-9-2016



### 4.2b Treatment analysis of Case 2 based on navel needling- The solution of Lei and Shui 病例2 脐针雷水解治疗分析

1. The outer Bagua regions: Zhen region represents foot 外八卦: 震为足
2. Navel hologram of Luoshu: Number 1 represents feet 洛书 人体全息图: 履一



4	9	2
3	5	7
8	1	6

12/11/20  
16

#### 4.2b Treatment analysis of Case 2 based on navel needling- The solution of Lei and Shui 病例2 脐针雷水解治疗分析

3. Zhen region represents the Liver which dominates tendons; Kan region represents the Kidney which dominates bone and generates marrow. 震卦为雷为肝，肝主筋；坎卦为水为肾，肾主骨生髓
4. The meaning of the solution of Lei and Shui: The storm bursts with a tremendous peal of thunder and a rush of rain. The winter snow melts, the spring season bursts forth, the difficult problems are solved. 雷水解的卦意：卦意是雷雨大作，冬雪春化，解开困顿。

There are four overlapping graphs - the more treatment approaches overlap, the better the effect will be. 四图共参，套图越多疗效越佳。

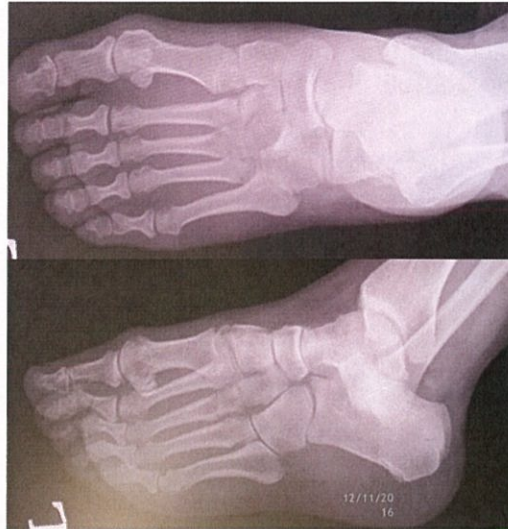#### 4.2c Case 2 Treatment effect based on navel needling 病例2 脐针治疗后疗效

- ▶ No pain and cold feeling, no obvious swelling, could bear weight and no limitation of movement. 患者局部疼痛冰冷消失，水肿已不明显，已能承重并活动不受限。
- ▶ Foot CT Scan Review Report on 11/10/2016 and 1/11/2016: comminuted fractures have been recovering very well on the distal medial cuneiform and base of the second metatarsal, the base of the 1<sup>st</sup>, 3<sup>rd</sup> and 4<sup>th</sup> metatarsals also. 2016年10月11日和11月1日 脚部CT复查报告：跗跖关节粉碎性骨折、楔状骨和第二跖骨底粉碎性骨折和第一，三，四跖骨底骨折恢复的非常好。

12/11/20  
16



## Foot X-ray after treatment on 1-11-2016



## 5. Conclusion (Advantages)结论(优势)

The invention of Navel Acupuncture Therapy has written a new page in the history of TCM and there are many advantages 易医脐针的发明在中医史上写了一个新的篇章，具有很多优势:

1. It is a complete theoretical system 有完整的理论体系
2. The obvious characteristics of acupuncture are present 有明显的针法特点
3. It has wide therapeutic range 有广泛的治病范围
4. It has rapid clinical effect 有快速的临床疗效
5. It has high satisfaction levels from patients 有很高的病人满意度

12/11/2016  
16

## 5. Conclusion (challenges)结论(挑战)

1. It is a very new therapy and there are not many practitioners who are applying it at this stage.是一个非常新的治疗体系，目前并没有很多医生和患者在临床上用它。
2. It is difficult to understand the esoteric theory of Yi Jing for many people.很多人很难理解易经的深奥的理论
3. The technical difficulty of manipulation concerning the needling depths where it takes experience to know exactly the various layers on the umbilical wall. It needs precise attention to avoid creating any danger to the patients, so we strongly recommend that practitioners should get precise training on navel acupuncture therapy before putting any needles in the umbilical wall.关于针刺深度是操作技术上的难度，需要知道在脐壁上的各个层，以避免给患者造成任何危险，因此，我们强烈建议，医生应该在肚脐针疗法之前，必须得到精确严格的训练。

12/11/20  
16

## 参考文献 Reference

- 齐永 (2008). 脐针疗法[Therapy]
- 齐永Qi,Y. (2013). 易医解密[Decrypting I-ching medicine]
- 齐永Qi,Y. (2015). 脐针入门[M] [The manual enter of Naval Acupuncture]. 北京:人民卫生出版社People's medical publishing house.
- [www.dayizhidao.com](http://www.dayizhidao.com)
- Bo, Z. Y. (1999). 腹针疗法 [Abdominal acupuncture therapeutic techniques]. 中国科学技术出版社 [Beijing, China: Chinese Science & Technology Press].

12/11/20  
16



谢谢 Thank You



### 病例3胸痛 Case3-Chest pain

- ▶ 82岁女性，阵发性胸闷胸痛头晕心悸2天。 Female 49 years old, paroxysmal oppressed sensation and pain in the chest, palpitation and dizziness for 2 day.

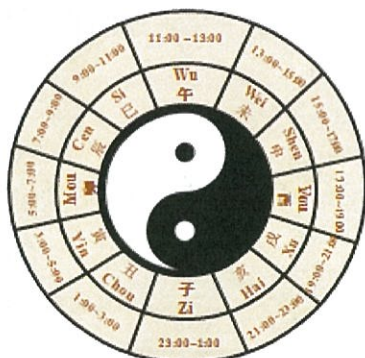心电图报告ECG report:

- 1.窦性心律Sinus rhythm
- 2.窦性心律不齐Sinus arrhythmia
- 3.一度房室传导阻滞  
First degree AV block
- 4.右束支阻滞Right bundle  
branch block
- 5.可能性下壁心肌Possible  
inferior myocardial infarction

她家庭医生建议  
她马上去住院装  
心脏支架  
Her family  
doctor advised  
her to go to the  
hospital for a  
heart stent right  
away.

## 病例3脐针治疗

### Case3-Navel Acupuncture treatment



1. 朱雀三针加坎治疗一周  
Si-Wu-Wei + Zi ,  
for one week  
treatment

2. 四隅位治疗一周  
Chou-Chen-Wei-Xu for  
one week treatment

12/11/20  
16

## 病例3脐针治疗疗效

### Case3 - The treatment result of Naval Needling

ECG report after Naval needling treatment for 2 weeks:  
脐针治疗2周后的心电图报告：

- ▶ Sinus rhythm, sinus arrhythmia and first degree AV block. 窦性心律, 窦性心律不齐 和 一度房室传导阻滞
- ▶ There is no more right bundle branch block and possible inferior myocardial infarction. The GP believed that she doesn't need to go to the hospital for a heart stent right now. 已没有右束支阻滞和可能性下壁心肌梗死。家庭医生认为现在已没有必要再心脏支架

12/11/20  
16



## 病例3心电图报告 Case3-ECG report

### 治疗前 Before treatment

ID: Female 35+ years

Vent. rate 54 bpm  
PR int. 246 ms  
QRS dur. 130 ms  
QT/QTc int. 488/ 474 ms  
P/QRS/T axis 60/ -4/ -1  
RV5/SV1 amp. 1.550/ 0.100 mV  
RV5+SV1 amp. 1.650 mV

1100 Sinus rhythm  
231 First degree AV block  
150 Right bundle branch block  
624 Possible inferior myocardial infarction, age undetermined  
150 \*\* abnormal ECG \*\*

### 治疗 2 周后 After treatment for 2 week

ID: Female 35+ years

Vent. rate 57 bpm  
PR int. 244 ms  
QRS dur. 88 ms  
QT/QTc int. 452/ 447 ms  
P/QRS/T axis 64/ -5/ 12  
RV5/SV1 amp. 1.620/ 0.370 mV  
RV5+SV1 amp. 1.990 mV

1100 Sinus rhythm  
1102 Sinus arrhythmia  
231 First degree AV block  
150 \*\* abnormal ECG \*\*

12/11/20  
16

